

Rounds

Animal Health
Department

Medical Rounds

"medicine for all"



Caring for Stranded Marine Animals

NATIONAL
MARINE
LIFE
CENTER

Notes

Veterinary Research
Department

Under the microscope

rwilliams@nmlc.org

Rounds Notes is a report on the health of animals at the National Marine Life Center from Sea Rogers Williams VMD for the staff, volunteers, and community of the center including professionals involved the captive care of similar species, the views expressed are not necessarily that of NMLC. Information in Rounds Notes should be considered confidential and used solely to benefit the health of aquatic animals everywhere.

February 16, 2009

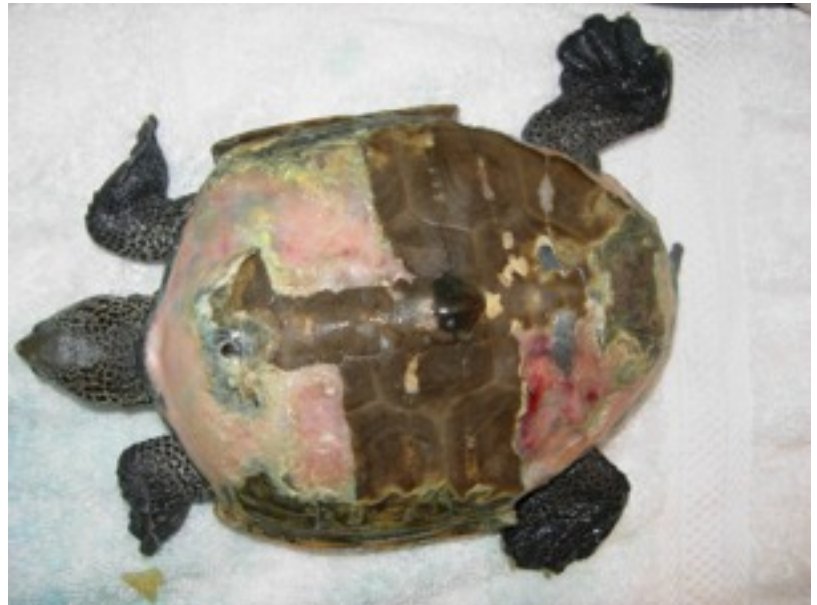Rounds Notes

3: 6-7 (2010)

Clinical Update:: 'Turtle on the Half Shell'

culinary tittle by Brian Moore

Patty's shell continues to be peeled away at each examination as the pseudoshell forms relatively quickly under the necrotic bone of the scutes. Being careful not to avulse the pseudoshell with a resultant ulcer and exposed tissue, the boney plates are easily wiggled from their mechanical hold and removed. The tissue is cleaned with chlorohexiderm and later dilute betadyne. Muracin ointment is applied to the fleshy areas and a top dressing of SSD ointment is used to protect the exposed skin, these treatments are done daily. We continue with antibiotics [enrofloxacin, compounded 13mg/ml, @ 10mg/mg, 0.5cc PO q5d]. Some blisters that formed in the pseudoshell were cultured and there was no bacterial growth. It now appears clear that we will soon loose the entire bony carapace from avascular osteonerosis.



The ultrasound images were reviewed and one interesting note was the lack of any follicular activity, which means that the metabolic stress of this episode may have caused regression or cessation of reproductive activity, which is a good thing, Patty has enough to do regrowing her shell. Her blood heart contractility and internal blood flow all look good on the Doppler exams,




the urinary bladder is large (typical but why an aquatic turtle would 'hold it' is beyond me), and I have measured and documented the enlarged left renal area so we can monitor this finding.

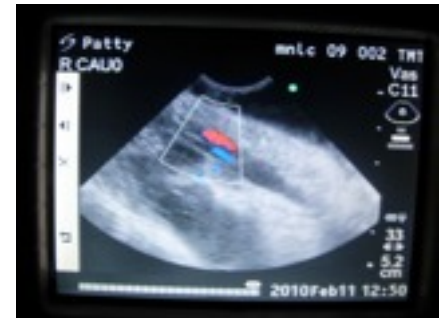There was some flaking of the plastron at today's exam which is a little concerning as the plastron has so far be relatively unaffected, will have to keep a close eye on this area.

As far as her eyes and hindlimb strength and coordination go she seems to have made a remarkable recovery.

Richard Dawkins discusses a summary of recent advancement in our understanding of turtle evolution in his book "The Greatest Show on Earth." I found it interesting that the carapace may have developed separately and much later then the plastron, and in aquatic turtles, where the lower plastron may have been a greater advantage to turtle ancestors that lived in the water column but had to surface to breath. Further, all modern turtles and terrapins may have descended from these marine relatives in a second invasion of the land. Of course, all of this took place a long time ago so some of the details remain sketchy, but the separate development of the plastron from the carapace may explain why the plastron has so far been largely unaffected by an injury so severe that it may cause the complete loss of all bones of the carapace.



Another major question that hunts me is where the developmental impetus for osteogenesis (new bone growth) lies. Were there dermal zones with in the developing epidermis that are keyed to bone formation which become the bony plates of the carapace, that have now been lost following an episode of a lack of blood flow during the period of freezing which occurred almost a full year ago ? We know her perfusion is good now, and can evaluate her heart and major arteries and veins with ultrasound, and evidence of new growth which is supporting the pseudoshell. Alternatively, is the pseduoshell pleuri-potential like steam cells, and does it have the ability to form new centers of osification ? These questions are partly musings of a clinician trying to stay one jump ahead of a complications with a new disease and healing process, but also have serious implications for our understanding of of number of issues;



- 1) We will gain a better understand of the tolerances for new growth and healing of the terrapin carapace.
- 2) Correlation with avascular necrosis and microvascular disease with late effects on bone growth which is a problem for humans suffering severe frost-bite, particularly children with active growing bones, a situation has occurs through a turtles' life.
- 3) Following the healing phase of severe carapace injury in terrapins may shed light on the early evolutionary history of turtles.
- 4) All of which improves our understanding of a subject near and dear to my heart as well as my arch-hero Sir David Attenborough, that of understanding "life of earth'.

C Rogers Williams VMD

Sea Rogers Williams VMD
attending veterinarian and director of science

